

Morphometric Analysis of Greater Palatine Foramen and the Adjacent Structures: Forensic Odontology Study using CBCT

WINNIFRED CHRISTY¹, S ANNAPOORANI², T JONES RAJADEVA THAMBI³, MAHALAKSHMI⁴

ABSTRACT

Introduction: Sexual dimorphism plays a pivotal role in many instances, including solving medicolegal problems, anthropological studies, sorting out victims of natural calamities and man-made calamities. Among various parameters available for sexual dimorphism, structures of the oral cavity play an important role. The use of Cone Beam Computed Tomography (CBCT) is convenient and provides accurate measurements with the help of digital software.

Aim: To determine the role of Greater Palatine Foramen (GPF), its Greater Palatine Canal (GPC) and relation with the adjacent structures like Nasopalatine Foramen (NPF) and Lesser Palatine Foramen (LPF) in elucidating the level of sexual dimorphism using CBCT images, while enhancing the information on anatomy of Greater Palatine Foramen (GPF).

Materials and Methods: This cross-sectional forensic odontology study was conducted in the Department of Oral Medicine and Radiology, CSI College of Dental Sciences and Research, Madurai, Tamil Nadu, India, and was performed using 50 males and 50 females CBCT images of patients between age 18 to 45. The CBCT data were collected from January 2021 till January 2022, and the obtained data were analysed from March 2022 till April 15, 2022. These were analysed using Planmeca imaging software. Measurements of GPF length, angulation with respect to Hard Palate (HP), relation between NPC and GPF, distance

between GPC and Mid Maxillary Suture (MMS). Its relation to LPF and dimensions of GPF at opening of oral cavity were done. Finally, all measures were subjected to statistical analysis using IBM Statistical Package for the Social Sciences (SPSS), version 28.0. Independent t-test was used for analysis of difference between male and female measurements.

Results: The GPC length on right (male: 13.2570, female: 12.3628) and left (male: 12.8089, female: 12.2780), angulation between left GPC and hard palate (HP) (male: 61.1379, female: 57.4964), angle between GPF and NPC left (male: 28.6208, female: 26.5024), distance between GPC and MMS left (male: 15.1625, female: 14.5350) and Anteroposterior (AP) dimensions of GPF on right (male: 5.5402, female: 4.2314) and left-side (5.4934, female: 4.4576), Transverse dimension of GPF on right (male: 2.6752, female: 2.0528) and left (male: 2.6616, female: 2.1544) showed statistically significant difference between male and female CBCT images, while the measures were significantly higher in males.

Conclusion: The CBCT images provided reliable measurements of the areas of interest. The present study results highlight a statistically significant difference between male and female, where males showed higher measurements in most instances. A more precise morphological measurement of GPF in relation to adjacent structures such as NPC, MMS proves to have sexual dimorphism in humans.

Keywords: Cone beam computed tomography, Medicolegal cases, Nasopalatine foramen, Sexual dimorphism

INTRODUCTION

One of the most amazing naturally occurring phenomena in various animals, including humans, is sexual dimorphism [1,2]. Men and women vary anatomically in many ways that go far beyond physical appearance or the presence of primary and secondary sexual characteristics. Despite having the same number of bones, males and females display a variety of differences that are not always obvious. Careful research is, therefore, required to identify the sexual dimorphism that exists in humans so that it can be effectively applied when necessary. According to reports, the skull and pelvis continue to be the most accurate sex indicators [3]. Additionally, it has been demonstrated that there are differences in size, shape, and location between males and females in the foramen of the head and neck area, such as the foramen magnum, mental foramen, infraorbital foramen, and carotid canal. They are regarded as being structures with greater clinical relevance and significance [3]. Anatomical structures like the HP are heat resistant and continue to be an ideal structure for sex determination, according to a study by Holland [4] that, found that even in conditions of extreme heat, the cranial bones experience minimal morphological changes. The differences in HP dimensions have been thoroughly researched. According to a recent study by Mustafa AG et al., the structures of the HP, such as its dimensions and the morphology of the NPF, vary between males

and females [5]. The promise of GPF's sexual dimorphism traits, which have gone largely unnoticed over time, should also be given top priority. The quantity of information accessible for each person is directly correlated with the validity and legitimacy of the process of human identification or sexual dimorphism. In most cases, the full skeleton won't be accessible, so the maximum amount of data cannot be retrieved. In such cases, meticulous assessment of all available bone will be an ideal condition for sex determination [6] and in such conditions, GPF plays a pivotal role. Thus, the analysis of GPF in relation with adjacent anatomic structures including NPF, MMS and LPF results in better sensitivity and reliability. Adding to this, the above mentioned structures are often stable and exhibit less deviation from normal [5].

The majority of research on the anatomical changes in the cranial base and HP has been done on dried bones [6-9]. Due to CBCT's benefits of high-resolution pictures, quicker, more efficient imaging, and less radiation exposure, its usage of dried bones has been eclipsed. In literature, few articles have been put forth demonstrating the anatomical variances of GPF using CBCT [8-12]. The hard palatal length and width is higher in males than females [8] and majority belonged to brachystaphyline type. The Nasopalatine Canal (NPC) proves to show higher measurements in male and the size is irrespective of the type of canal [9]. These articles were

mainly emphasising the anatomic aspects of GPF among different populations. This is the first kind of study emphasising the forensic property of GPF using CBCT. The present study is deviated from all the conventional measures by using CBCT as a tool to examine GPF for its sexual dimorphism.

With this background, the aim of the study is to determine the role of GPF, its GPC and relation with the adjacent structures like NPF and LPF in elucidating the level of sexual dimorphism using CBCT images while enhancing the information on anatomy of GPF.

MATERIALS AND METHODS

This cross-sectional forensic odontology study was conducted in the Department of Oral Medicine and Radiology, CSI College of Dental Sciences and Research, Madurai, Tamil Nadu, India. The CBCT data were collected from January 2021 till January 2022, and the obtained data were analysed from March 2022 till April 15, 2022. The assessment of sexual dimorphism using GPF, inclusive of the adjacent structures was carried out using 100 CBCT images (50 males and 50 females) of complete maxilla. The CBCT images of the patients, who were advised to undergo imaging for dental treatment were collected from archives. The CBCT images were obtained using standard exposure (85 kVp, 5-7 mA for scanning time of 14 seconds) and patient positioning protocols with CBCT unit (Planmeca Promax 3D Classic CBCT Unit). The obtained images were then analysed using Planmeca Romexis 3D imaging software, which provides detailed dimensional measurements of all anatomic structures under consideration.

Sample size calculation: Sample size adequacy for the present study was calculated using G Power 3.1.9.7 with effect size of 0.32 [13] and actual Power of 0.95.

Inclusion criteria:

- Patients above 18 years of age.
- Complete maxillary arch CBCT image.
- Images with no artifacts and no compromise in quality.

Exclusion criteria:

- Partially or completely edentulous maxilla.
- Presence of any disease condition in jaw- cancer, vascular malformations, benign tumour etc.
- Patients currently undergoing orthodontic treatment.
- Patients with congenital abnormalities such as cleft palate.
- Patients having high arch palate.

Study Procedure

A morphometric analysis was performed. Initially, the GPF was located in Axial Plane (AxP), using this GPC was located in Sagittal Plane (SP). Further, two stabilised planes Plane 1 and 2 were established as reference to avoid bias between patients while undergoing further measurements.

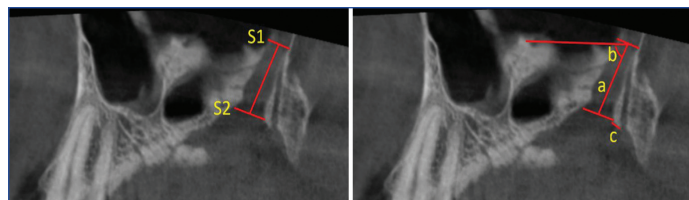
Plane 1: S1- at the base of pterygopalatine fossa

Plane 2: S2- at the level of GPF [Table/Fig-1]

Following morphometric measurements were made by a single investigator, expressed in millimeters for males and females.

In sagittal plane [Table/Fig-2]:

- Length (Le) of GPC from center of S1 to S2 in right (Le RGPC) and left (Le LGPC) sides [Table/Fig-2a].
- Angulation of GPC with respect to line parallel to HP in right (A RGPC-HP) and left (A LGPC-HP) sides [Table/Fig-2b].
- Distance between GPF and the nearest LPR in right (D RGPF-LPF) and left (D LGPF-LPF) sides [Table/Fig-2c].
- AP diameters of GPF at S2 in right (AP-RGPF S2, TR-RGPF S2) and left (AP-LGPF, TR-LGPF) sides.

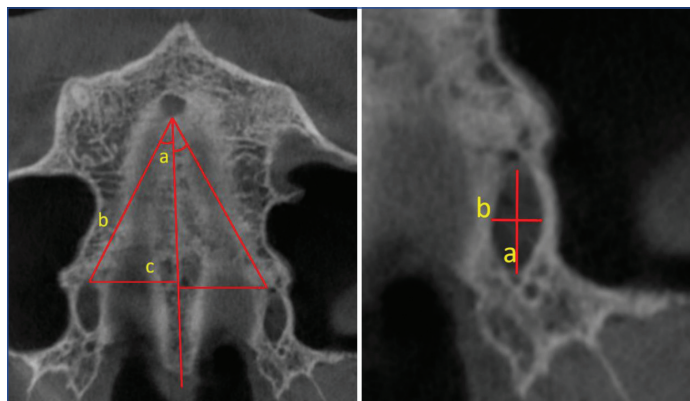


[Table/Fig-1]: Greater Palatine Canal in sagittal plane, denoting the position of S1.
[Table/Fig-2]: GPC: a) Length of GPC; b) Angle between GPC and a line parallel to Hard Palate (HP); c) Opening width of GPF. (Images from left to right)

- The number of LPF present in right and left-sides (Number of LPR-right, number of LPR-left).
- The shape or course of GPC.

In Axial Plane (AxP) [Table/Fig-3,4]:

- AP and TR diameters of GPF in right (AP-RGPF, TR-RGPF) and left (AP-LGPF, TR-LGPF) sides [Table/Fig-4a,b].
- Distance (D) between upper end of GPF to lower center of NPF in right (D NPF-RGPF) and left (D NPF-LGPF) sides [Table/Fig-3b].
- Angle (A) formed between upper end of GPF to lower center of NPF and MMS in right (A RGPF-NPF-MMS) and left-sides (A LGPF-NPF-MMS) [Table/Fig-3a].
- Distance between upper end of GPF to MMS (D RGPF-MMS, D LGPF-MMS) [Table/Fig-3c].



[Table/Fig-3]: GPF in Axial Plane (AxP): a) Angulation between GPF and MMS; b) Distance between GPF and NPF; c) Distance between GPF and MMS.
[Table/Fig-4]: GPF in Axial Plane (AxP): a) AP length of GPF; b) TN width of GPF. (Images from left to right)

D NPF-GPF, A GPF-NPF-MMS were measured to analyse variations in relation between GPF, NPF, MMS in view of facilitating easy identification of GPF during surgical procedures and also, for the purpose of sexual dimorphism.

STATISTICAL ANALYSIS

The statistical analysis was carried out in IBM SPSS version 28.0. Descriptive statistics was carried out and reported as mean±Standard deviation. The association between males and females were assessed using independent student t-test. Paired sample test was done to find variations between right and left-sides in male and female, separately. Chi-square test was carried out to find age differences in males and females, separately. Following this multiple logistic regression analysis was carried out to frame the prediction model. From the regression analysis results, the values of constants and non standardised coefficients were fitted into formula along with the dependent variables.

$$Y = \text{Constant} + \beta_1 X_1 + \beta_2 X_2 + \dots + \beta_n X_n$$

where, Y is the value to be found, in our case gender, β_1, β_2 are non standardised coefficients, X_1, X_2 are dependent variables which are the morphometric measurements. The accuracy of the generated equation was then assessed by carrying out similar morphometric assessment in 30 CBCT images with hidden identity. The values were then entered in the generated prediction equation and cross-checked.

RESULTS

In the present study, a total of 100 CBCT images were examined, mean age of patients was 32.11 ± 8 years. Out of 100 patients involved, 50 males and 50 females, 200 canal morphologies were evaluated.

Measurement in Axial Plane (AxP)

A statistically significant difference was found between AP, TN width of GPF in both right and left-sides. Males showed a greater diameter, when compared to females. Left-side showed a significant difference in angulation between GPF and NPF, a higher value was seen in males (mean= 28.62°) than females (mean= 26.50°) similarly distance between GPF and MMS was higher in males (mean= 15.16 mm) than females (mean= 14.53 mm) [Table/Fig-5]. Distance between GPF and NPF in both right and left-sides, Angulation between GPF and NPF in right and distance from GPF to MMS in right-side showed statistically non significant results between males and females.

Measurements	Sex	N	Mean	Std. Deviation	t-value	p-value
AP- RGPF width	Male	50	5.5402	1.71631	4.798	<0.001*
	Female	50	4.2314	0.82784		
AP- LGPF width	Male	50	5.4943	1.36006	4.228	<0.001*
	Female	50	4.4576	1.00916		
TN- RGPF width	Male	50	2.6752	1.00823	3.779	<0.001*
	Female	50	2.0528	0.54766		
TN- LGPF width	Male	50	2.6616	0.81622	3.860	<0.001*
	Female	50	2.1544	0.41737		
D NPF-RGPF	Male	50	32.6673	3.59656	-0.025	0.490
	Female	50	32.6826	2.31473		
D NPF-LGPF	Male	50	32.6639	3.09444	0.410	0.341
	Female	50	32.4234	2.59365		
A RGPF-NPF-MMS	Male	50	28.0348	3.07714	-1.187	0.119
	Female	50	28.9120	60.65404		
A LGPF-NPF-MMS	Male	50	28.6205	3.35473	3.140	0.001*
	Female	50	26.5024	3.18097		
D RGPF-MMS	Male	50	14.7277	2.24920	0.436	0.332
	Female	50	14.5616	1.39137		
D LGPF- MMS	Male	50	15.1625	1.75152	2.121	0.018*
	Female	50	14.5350	1.07473		

[Table/Fig-5]: Axial Plane (AxP) measurements. Measurements were expressed in millimeters for males and females.

*Significant at the level of 0.05

AP-RGPF WIDTH: Anteroposterior width of right greater palatine foramen, AP-RLGPF WIDTH: Anteroposterior width of left greater palatine foramen, TN-RGPF WIDTH: Transverse width of right greater palatine foramen, TN-LGPF WIDTH: Transverse width of left greater palatine foramen, D NPF-RGPF: Distance between right greater palatine foramen and Nasopalatine Foramen, D NPF-LGPF: Distance between left greater palatine foramen and nasopalatine foramen, A RGPF-NPF-MMS: Angulation between right greater palatine foramen and nasopalatine foramen with respect to Mid-Maxillary Suture (MMS), A LGPF-NPF-MMS: Angulation between left greater palatine foramen and nasopalatine foramen with respect to MMS, D RGPF-MMS: Distance between right greater palatine foramen and MMS, D LGPF-MMS: Distance between left greater palatine foramen and MMS

Measurements in Sagittal Plane

In sagittal plane, length of GPC in right and left-sides, angulation of GPC in left, distance between GPF and LPF in both sides showed statistically significant results ($p < 0.05$). All the other values showed non significant results [Table/Fig-6]. Additionally, the shape of GPC in sagittal plane was measured, this resulted that 83.23% of studied GPC showed straight path, while only a minor percentage of 16.77 showed curved path.

Prediction Formula

Two logistic regression analysis were carried out separately for axial and sagittal planes using only right-side values. Right-side values were chosen to formulate prediction equation as most of the measurements showed significant difference between male and female.

- Gender (in AxP): $-0.411 + 0.132 \text{ AP-RGPF} + 0.059 \text{ TN-RGPF} + 0.004 \text{ NPF-RGPF} - 0.001 \text{ A NPF-RGPF} + 0.002 \text{ D RGPF-MMS}$.

- Gender (in sagittal plane): $-2.105 + 0.94 \text{ Le RGPC} + 0.014 \text{ A RGPC-HP} + 0.165 \text{ D RGPF-RLPF} + 0.026 \text{ AP RGPF}$ at S2

In both prediction equations, values less than one denotes female and more than one denotes male. The accuracy of the prediction equations was tested using 30 unidentified CBCT images and resulted to be 83% in AxP and 78.3% in sagittal plane.

Paired t-test within Male and Female

The paired t-test was carried out to compute differences between sides in males and females, separately. Almost all parameters resulted in a significant ($p < 0.05$) difference between sides in females and males [Table/Fig-7]. Of which comparatively strong statistical difference (p -value < 0.01) was found in TN GPF, Distance between right GPF and NPF in females. While in males, a strong statistical difference was found in AP GPF, TN GPF, length of right GPF and angulation of right GPF. From the results, it can be interrupted that in females, most of the measured parameters showed greater mean

values in left than in right-side [Table/Fig-7]. On the other hand, males show greater mean values in right than in left-side.

DISCUSSION

A number of techniques have been used in the past to determine a person's sex, including visual inspection, tooth eruption order, chemical and physical analysis of calcified structures, Deoxyribonucleic acid (DNA) testing and examination of different skeletal structures [14]. Because of the durability and secluded anatomic location in the base of the cranium, HP is one of the essential structures for sex identification. Likewise, the use of GPF as scientific evidence pertained to sexually dimorphic characteristics exhibited by human skeleton are used for administration of law and justice [15,16]. Numerous studies using both dry skull and three-dimensional imaging have been done in the literature to analyse the mastoid triangle, foramen magnum, HP, zygomatic arch, supraorbital ridges, orbital margins, and the position of the pterion, among other

S. No.	Measurements	Female mean	N	Std. Deviation	p-value	Male mean	N	Std. Deviation	p-value
1	AP RGPF	4.2065	50	0.81733	0.001*	5.5402	50	1.71631	<0.001*
	AP LGPF	4.4690	50	1.01637		5.4943	50	1.36006	
2	TN RGPF	2.0600	50	0.55094	<0.001*	2.6752	50	1.00823	<0.001*
	TN LGPF	2.1671	50	0.41175		2.6616	50	0.81622	
3	D NPF- RGPF	32.7224	50	2.32132	<0.001*	32.6673	50	3.59656	<0.001*
	D NPF- LGPF	32.4304	50	2.62005		32.6639	50	3.09444	
4	A NPF- RGPF	39.1400	50	61.26094	0.009*	28.0348	50	3.07714	<0.001*
	A NOF- LGPF	26.5004	50	3.21390		28.6205	50	3.35473	
5	D RGPF- MMS	14.5710	50	1.40418	<0.001*	14.7277	50	2.24920	0.004*
	D LGPF- MMS	14.5286	50	1.08490		15.1625	50	1.75152	
6	Le RGPC	12.3069	50	1.33450	0.003*	13.2570	50	1.21673	<0.001*
	Le LGPC	12.2569	50	1.27034		12.8089	50	1.88110	
7	A RGPC-HP	59.4153	50	4.83084	0.001*	61.2259	50	7.14339	0.001*
	A LGPC-HP	57.6178	50	5.82636		61.1375	50	12.33248	
8	AP RGPF-S2	5.4318	50	1.82205	0.001*	6.5916	50	2.36855	<0.001*
	AP LGPF-S2	4.9931	50	2.07827		6.6091	50	2.27333	
9	D RGPF-RLPF	1.9202	50	0.84859	0.009*	2.9018	50	1.31352	0.011*
	D LGPF-LLPF	1.9759	50	0.71636		2.5327	50	0.98178	

[Table/Fig-6]: Sagittal plane measurements. Measurements were expressed in millimeters for males and females.

*Significant at the level

Le RGPC: Length of right greater palatine canal; Le LGPC: Length of left greater palatine canal, A RGPC-HP: Angle between right greater palatine canal and Hard Palate (HP), A LGPC-HP: Angle between left greater palatine canal and HP, AP RGPF S2: Anteroposterior width of right greater palatine foramen at S2, AP LGPF S2: Anteroposterior width of left greater palatine foramen at S2, NUMBER OF LPR-RIGHT: Total number of lesser palatine foramen (LPP) in right, Number of LPR- Left: Total number of LPP in left, D RGPF-RLPF: Distance between the right greater palatine foramen and the nearest LPP, D LGPF-LLPF: Distance between the left greater palatine foramen and the nearest LPP

Measurements	Sex	N	Mean	Std. Deviation	t- value	p-value
Le RGPC	Male	50	13.2570	1.21673	3.314	<0.001*
	Female	50	12.3628	1.37861		
Le LGPC	Male	50	12.8089	1.88110	1.622	0.050*
	Female	50	12.2780	1.26610		
A RGPC-HP	Male	50	61.2259	7.14339	1.598	0.057
	Female	50	59.2140	4.98869		
A LGPC-HP	Male	50	61.1375	12.33248	1.865	0.033*
	Female	50	57.4964	5.83009		
AP RGPF S2	Male	50	6.5916	2.36855	2.2650	0.005*
	Female	50	5.4476	1.80680		
AP LGPF S2	Male	50	6.6091	2.27333	3.363	<0.001*
	Female	50	4.996	2.05748		
Number of LPR-RIGHT	Male	50	2.09	0.802	1.205	0.095
	Female	50	1.94	0.620		
Number of LPP- LEFT	Male	50	2.14	1.025	1.011	0.142
	Female	50	2.26	0.803		
D RGPF-RLPF	Male	50	2.9018	1.31352	4.309	<0.001*
	Female	50	1.9320	0.84402		
DT LGPF-LLPF	Male	50	2.5327	0.98178	3.104	0.001*
	Female	50	1.9876	0.71381		

[Table/Fig-7]: Measurements of right and left-sides and their significance in males and females. Measurements were expressed in millimeters for males and females.

*Significant at the level of 0.05; AP-RGPF width: Anteroposterior width of right greater palatine foramen, AP-RLGPF width: Anteroposterior width of left greater palatine foramen, TN-RGPF width: Transverse width of right greater palatine foramen, TN-LGPF width: Transverse width of left greater palatine foramen, D NPF-RGPF: Distance between right greater palatine foramen and nasopalatine foramen, D NPF-LGPF: Distance between left greater palatine foramen and nasopalatine foramen, A RGPF-NPF-MMS: Angulation between right greater palatine foramen and nasopalatine foramen with respect to MMS, A LGPF-NPF-MMS: Angulation between left greater palatine foramen and nasopalatine foramen with respect to MMS, D RGPF-MMS: Distance between right greater palatine foramen and MMS, D LGPF-MMS: Distance between left greater palatine foramen and MMS, Le RGPC: Length of right greater palatine canal, Le LGPC: Length of left greater palatine canal, A RGPC-HP: Angulation between right Greater palatine canal and HP, A LGPC-HP: Angulation between left Greater palatine canal and HP, AP RGPF-S2: Anteroposterior width of right greater palatine foramen at S2 in sagittal plane, AP LGPF-S2: Anteroposterior width of left greater palatine foramen at S2 in sagittal plane, D RGPF-RLPF: Distance between right greater palatine foramen and the nearest lesser palatine foramen, D LGPF-LLPF: Distance between left greater palatine foramen and the nearest LPP

structures [17-20]. The few studies that are currently accessible have used dried bones [13,21], and very few have used computed tomography [11,12] for GPF evaluation. Various morphometric

measurements were taken with a vernier calliper in traditional studies using dry skulls, and they were susceptible to examiner variability [7]. The use of CBCT imaging now-a-days has become inevitable.

The accuracy and less time consumption of CBCT imaging systems has paved way for its application in studying the anatomic variations among skeletal structures. The accuracy of using CBCT in measuring the structures of interest is appreciable and with this key point the use of CBCT was considered as a foreseeable measurement tool in the present study. Stable HP landmarks were examined using CBCT in the present research, which yields more accurate results. The primary goals of the present study were to improve the data, that was already known and to add information about sexual dimorphism, that would aid in separating the human remains into males and females.

In the present study, there was substantial variability in measurements of GPF with its adjacent structures between males and females. When taking the dimensions of GPF in sagittal plane, it was found that the AP dimension of GPF was greater in males than females in both right and left-side. It can be interpreted that, females have a smaller GPF when compared to males. The mean AP and TN width of GPF obtained in our study is in accordance with study conducted by Nimigean V et al., [14]. When right and left-side was compared in males and females separately, it resulted in a statistically significant result, with greater values in left-side in females and

to females, but there was no statistically significant difference. When looking to side differences in males and females- females had increased length and angulation in right while males in left-side. When looking into the shape of GPC, almost all were straight in the present study as the part of canal below the base of pterygopalatine fossa was only studied. The findings of the present study are in harmony with studies conducted in a group of Lebanese population and Saudi population [Table/Fig-8] [11,12,14,21]. Their findings also reveal presence of significantly higher measurements in sagittal plane, when GPF and its relation to midline is taken into account. The harmony between the results of current study and previous studies provides validity to the present study reports and design.

Based on the included parameters, the formulated gender prediction model both for axial and sagittal measurements were tested and resulted to have good sex determination accuracy of 83% and 78.3% in axial and sagittal planes, respectively. The present study confirms that GPF, GPC like any other cranial structures is subject to sexual dimorphism. In the present study, differences were reported with respect to dimensions of GPF, length and angulation of GPC and its relation with adjacent structures like NPF, LPF. Side-related discrepancies separately in males and females, were also reported.

Ref. No.	Author's name and year	Place of study	Number of subjects	Parameters assessed	Morphometric measurements				
					Transverse dimensions	AP diameter	Distance to midline	GPF-NPF distance	GPF-NPF angle
[11]	Alotaibi MK et al., 2018	Saudi dental patients	182 scans	Morphometric assessment of NPF, GPF	M-3.33; F-2.99.	M-4.16, F-4.04	M-14.70, F-14.09	M-38.50, F-36.99	M-31.26, F-30.46
[12]	Aoun G et al., 2015	Lebanese population	58 scans	Morphometric assessment of GPF		M (R)-6.305, M (L)-6.29; F (R)-5.00, F (L)-5.17	M (R)-16.88, M (L)-15.79; F (R)-15.61, F (L)-14.08		
[14]	Nimigean et al., 2013	South Eastern European population	100 dry skulls	Morphometric assessment of GPF	3.0	4.9	14.5		
[21]	Patil M and Sheelavant S, 2019	---	123 dry skulls	Morphometric assessment of GPF	M (R)-3.41, M (L)-3.44; F (R)-2.88, F (L)-2.78.	M (R)-4.87, M (L)-4.99; F (R)-4.58, F (L)-4.48.	M (R)-14.67, M (L)-15.09; F (R)-14.59, F (L)-14.7		M (R)-20.79, M (L)-20.81; F (R)-20.56, F (L)-20.58
	Present study	CSI College of Dental Sciences	100 scans	Morphometric assessment of NPF, GPF	M (R)-2.67 M (L)-2.66 F (R)-2.05 F (L)-2.15	M (R)-5.54 M (L)-5.49 F (R)-4.23 F (L)-4.45	M (R)-14.72 M (L)-15.16 F (R)-14.56 F (L)-14.53	M (R)-32.66 M (L)-32.66 F (R)-32.68 F (L)-32.423	M (R)-28.03 M (L)-28.62 F (R)-28.91 F (L)-26.50

[Table/Fig-8]: Characteristics of previous studies [11,12,14,21].

greater right-side values in males. Unlike the past studies [5,21], which concluded to have no statistically significant difference in the distance between GPF and MMS, the present study found to have statistically significant difference between males and females in left-side, with males covering more distance in both right and left-sides. When analysing the relation between GPF and NPF, it was found that right-side showed significantly higher values than left-side in males and females. Like the above factors, males had higher angle and distance compared to females. This further adds on that, the position of GPF shows wide variation when observed with respect to NPF. From the AxP measurements, it can be stated that HP structure, especially GPF shows differences among males and females and even side differences in each gender.

The sagittal plane measurements include length of GPC, angulation of canal, AP dimension of GPF at S2, number of LPC and the distance between GPF and nearest LPF. From [Table/Fig-6], it is clear that, most of the above-mentioned parameters showed good statistical significance between male and female. Males had a greater length of canal in both right and left-sides. The canal angulation in females were more acute than males when measured with respect to HP and a line connecting S1 and S2 in sagittal plane, on comparing the distance between GPF and the nearest LPF, it can be concluded that, the LPF was more adjacent in female, while LPF was located far in males. Males had higher number of LPC, when compared

Limitation(s)

The major limitation of the study was small sample size and restriction to limited group of population. The value of the present study can be improvised, by expanding it to a larger scale of population and comparing with various groups of people.

CONCLUSION(S)

Although various parameters are available for forensic identification, thorough analysis of GPF, GPC can serve as an additional tool for sex determination. Various parameters pertained to GPF showed dimorphism. Additionally, two multiple logistic regression models were designed to predict sex, which resulted in a satisfactory accuracy of 83% and 78.3%. This, method proves to be a reliable one for identification and would be of immense help in instances of gross damage of individuals or if, the quantity of human remains found is low. The differences shown above can be taken into account during GPN anaesthesia, to obtain high success rate and reduce difficulty, while locating the canal.

REFERENCES

- [1] Kleisner K, Tureček P, Roberts SC, Havičček J, Valentova JV, Akoko RM, et al. How and why patterns of sexual dimorphism in human faces vary across the world. *Sci Rep.* 2021;11:5978.
- [2] Nikitovic D. Sexual dimorphism (Humans). In: Bix HJ, ed. *International Encyclopedia of Biological Anthropology*. John Wiley & Sons, Inc.; 2018.

- [3] Rizell S, Barrenäs ML, Andlin-Sobocki A, Stecksén-Blicks C, Kjellberg H. Palatal height and dental arch dimensions in Turner syndrome karyotypes. *Eur J Orthod.* 2013;35(6):841-47.
- [4] Holland TD. Use of the cranial base in the identification of fire victims. *J Forensic Sci.* 1989;34(2):458-60.
- [5] Mustafa AG, Tashtoush AA, Alshboul OA, Allouh MZ, Altarifi AA. Morphometric study of the hard palate and its relevance to dental and forensic sciences. *Int J Dent.* 2019;2019:8647208.
- [6] Das S, Satapathy BC, Biswal R, Muni MK. Morphometric study of the greater palatine foramen in the dried bones of Eastern India. *Int J Anat Res.* 2018;6(3.2):5568-73. Lima LNC, Oliveira OF, Sassi C, Picapedra A, Júnior LF, Daruge Júnior E. Sex determination by linear measurements of palatal bones and skull base. *J Forensic Odontostomatol.* 2012;30(1):37-44.
- [7] Jacob M, Bindhu S, Avadhani R. Sex determination from hard palate measurements using palatine index with reference to its clinical implications. *Indian J Clin Anat Physiol.* 2016;3(2):186-88.
- [8] Khojastepour L, Haghnegahdar A, Keshkar M. Morphology and dimensions of nasopalatine canal: A radiographic analysis using cone beam computed tomography. *J Dent (Shiraz).* 2017;18(4):244-50.
- [9] Sarna K, Estreed MA, Sonigra KJ, Amuti T, Opondo F, Kamau M, et al. Anatomical patterns of the nasopalatine canal and incisive foramen in an African setting- a cross-sectional study. *Folia Morphol (Warsz).* 2021.
- [10] Friedrich RE, Laumann F, Zrnc T, Assaf AT. The nasopalatine canal in adults on cone beam computed tomograms- a clinical study and review of the literature. *In Vivo.* 2015;29(4):467-86.
- [11] Alotaibi MK, Alansari MA, Alqahtani JM, Alduhaymi AA, Assari A, Baseer MA. Evaluation of greater palatine foramen and incisive canal foramen among Saudi patients using cone beam computed tomography scans. *J Oral Health Comm Dent.* 2018;12(2):56-61.
- [12] Aoun G, Nasseh I, Sokhn S, Saadeh M. Analysis of the greater palatine foramen in a Lebanese population using cone-beam computed tomography technology. *J Int Soc Prev Community Dent.* 2015;5(Suppl 2):S82-88.
- [13] Johnston KM, Lakzadeh P, Donato BMK, Szabo SM. Methods of sample size calculation in descriptive retrospective burden of illness studies. *BMC Med Res Methodol.* 2019;19(1):9.
- [14] Nimigea V, Nimigea VR, Butincu L, Salavastru DI, Podoleanu L. Anatomical and clinical considerations regarding the greater palatine foramen. *Romanian Journal of Morphology and Embryology.* 2013;54(2):345-49.
- [15] Kamath V, Asif M, Shetty R, Avadhani R. Binary logistic regression analysis of hard palate dimensions for sexing human crania. *Anat Cell Biol.* 2016;49(2):151-59.
- [16] da Silva RH, de Oliveira RN. Forensic anthropology and molecular biology: Independent or complementary sciences in forensic dentistry? An overview. *Braz J Oral Sci.* 2008;7:1575-79.
- [17] Suazo GI, Zavando MD, Smith RL. Sex determination using mastoid process measurements in Brazilian skulls. *Int J Morphol.* 2008;26:941-44.
- [18] Kamath VG, Asif M, Shetty R, Avadhani R. Binary logistic regression analysis of foramen magnum dimensions for sex determination. *Anat Res Int.* 2015;2015:459428.
- [19] Monticelli F, Graw M. Investigation on the reliability of determining sex from the human os zygomaticum. *Forensic Sci Med Pathol.* 2008;4:181-86.
- [20] Bigoni L, Velemínská J, Brůžek J. Three-dimensional geometric morphometric analysis of cranio-facial sexual dimorphism in a Central European sample of known sex. *Homo.* 2010;61:16-32.
- [21] Patil M, Sheelavant S. Greater palatine foramen- morphometry, sexual dimorphism and clinical perspective. *Nat J Clin Anat.* 2016;5(4):219-27.

PARTICULARS OF CONTRIBUTORS:

1. Professor and Head, Department of Oral Medicine and Radiology, CSI College of Dental Sciences and Research, Madurai, Tamil Nadu, India.
2. Intern, Department of Oral Medicine and Radiology, CSI College of Dental Sciences and Research, Madurai, Tamil Nadu, India.
3. Reader, Department of Oral Medicine and Radiology, CSI College of Dental Sciences and Research, Madurai, Tamil Nadu, India.
4. Reader, Department of Oral Medicine and Radiology, CSI College of Dental Sciences and Research, Madurai, Tamil Nadu, India.

NAME, ADDRESS, E-MAIL ID OF THE CORRESPONDING AUTHOR:

S Annapoorani,
82B, South Masi Street, Madurai-625001, Tamil Nadu, India.
E-mail: annapooranipadma@gmail.com

PLAGIARISM CHECKING METHODS: [Jain H et al.]

- Plagiarism X-checker: Dec 05, 2022
- Manual Googling: Feb 14, 2023
- iThenticate Software: Mar 07, 2023 (3%)

ETYMOLOGY: Author Origin

EMENDATIONS: 6

AUTHOR DECLARATION:

- Financial or Other Competing Interests: None
- Was Ethics Committee Approval obtained for this study? Yes
- Was informed consent obtained from the subjects involved in the study? Yes
- For any images presented appropriate consent has been obtained from the subjects. NA

Date of Submission: **Dec 03, 2022**

Date of Peer Review: **Feb 15, 2023**

Date of Acceptance: **Mar 18, 2023**

Date of Publishing: **Jun 01, 2023**